

Radiology Quiz Case 1

Jairo Barros Filho, MD; Fayez Bahmad Jr, MD, PhD; Carlos A. C. P. Oliveira, MD, PhD;
 Brasilia University School of Medicine, Brasilia, Brazil

A 40-YEAR-OLD WOMAN PRESENTED WITH A 10-year history of pulsatile tinnitus in her right ear. The sound was coincident with her heartbeat and interfered with her hearing. It could be eliminated by

supravenous pressure in the right side of the upper part of the neck. An audiogram revealed normal hearing. Computed tomography of the temporal bones was performed (**Figure 1** and **Figure 2**).

What is your diagnosis?

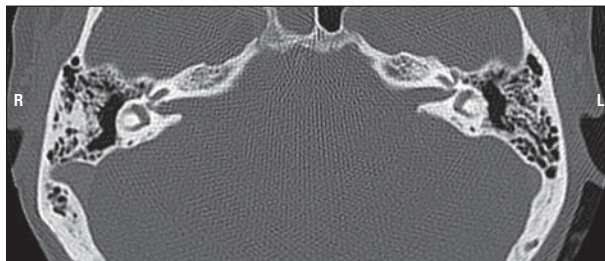


Figure 1.

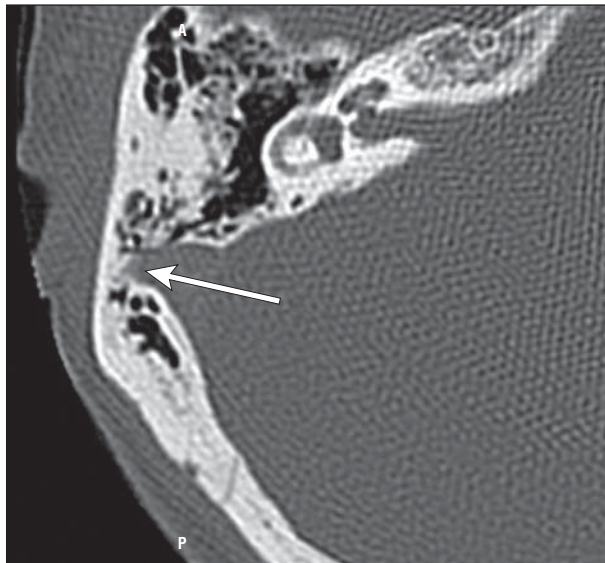


Figure 2.