

Corticosteroids Therapy for the Tinnitus Associated with Sudden Hearing Loss

Barreto MA^{1*}, Ledesma AL², de Oliveira CA³, Bahmad Jr F^{4,5}

¹Audiologist, Postgraduate Speech and Hearing/UFMS-RS, Educational Psychology/UFRRJ-RJ, Audiology and Neurotology/UFPE-PE, Master at Science Health and PhD in Science Health/ UnB-DF (University of Brasilia), Brazil

²Audiologist, Postgraduate Hospitalar Speech and Hearing/FAT-BA, Master at Science Health/ UnB-DF (University of Brasilia), Brazil

³Professor Emeritus at University of Brasilia, Brazil

⁴Specialist in Otolaryngology and Neurotology by Harvard Medical School, Boston, MA, EUA, PhD in Medical Science from the University of Brasilia, Brazil

⁵Professor at Health Sciences School at University of Brasilia, Brazil

Received Date: July 01, 2015, **Accepted Date:** October 21, 2015, **Published Date:** October 30, 2015.

***Corresponding author:** Barreto MA, SMHN QD 02 BLOCO C Ed. Dr. Crispim, Sala 515, Asa Norte, Brasília-DF, CEP 70710-149, Brazil, Tel: 613-328-6009, E-mail: nikebarr@hotmail.com

Abstract

Introduction: Tinnitus is a complex disorder of hearing and, in its most common form, is presented as a phantom auditory sensation which is not associated with an external sound stimulus. The sudden hearing loss is often characterized by an abrupt idiopathic onset. In up to 80% of these patients tinnitus is present and becomes the main complaint. In this research corticosteroids are the used therapy for sudden hearing loss.

Aim of study: This study characterized the tinnitus evolution in patients with sudden hearing loss and its therapy with corticosteroids.

Method: The study was done using analytical retrospective in 11 patients that were monitored after sudden hearing loss with tinnitus and underwent, before and after sudden hearing loss treated with oral and intratympanic corticotherapy: hearing evaluation, application of the Tinnitus Handicap Inventory and Visual Analogue Scale.

Results: Six patients showed improvement over the hearing and six showed improvement in their tinnitus, which was demonstrated by degrees of severity.

Conclusion: Patients with sudden hearing loss and tinnitus who underwent intratympanic and/or oral corticosteroids showed significant reduction of tinnitus.

Keywords: Tinnitus; Sudden hearing loss; Sudden deafness; Corticosteroids

Introduction

Tinnitus is a complex disorder of hearing and, in its most common form, is presented as a phantom auditory sensation which is not associated with an external sound stimulus [1]. Sudden hearing loss (SHL) was first described by De Kleyn, in 1944, and was defined as a hearing loss of at least 30 dB (decibels) at three sequential frequencies, in the standard pure-tone audiogram, over three days or less [2].

It may be characterized as an impairment of the inner ear and/or central auditory pathways, with intensity and frequency variable, ranging from mild ear feeling to total loss of hearing [3,4].

Studies of SHL show a wide distribution, ranging from 5 to 30 cases per 100,000 per year, with a population average of 50-60 years and no sex preference. In most cases, there is an unilateral hearing loss, with bilateral involvement reported in less than 5% [2]. Hypotheses are proposed to explain the pathogenesis of sudden hearing loss as the vascular, the viral, the autoimmune and the rupture of membranes one. However, the current trend is to consider the sudden hearing loss as a disease of multifactorial etiology [3]. In

many cases, the etiology remains unknown and constitutes a major challenge, even after complete otologic evaluation, and these cases are classified as idiopathic sudden hearing loss [4]. The treatment of sudden hearing loss is based on its etiology. In idiopathic cases, the oral corticosteroids are widely used. Intratympanic dexamethasone has been trialled in patients with sudden hearing loss, because it provides a high concentration of steroids in the labyrinth in animal models [2], although its evidence is conflicting.

SHL is a debilitating condition not completely understood often accompanied by tinnitus. However, one of few theories, trying to explain its mechanism associates this symptom with a maladapted attempt of a cortical reorganization process due to peripheral deafferentation [5]. Patients are very frustrated by residual tinnitus, even after the treatment's accomplishment, and ask doctors about residual tinnitus prognosis at the final day of medical treatment for SHL.

Regarding how to assess the improvement of tinnitus, Figueiredo et al. [6] points out that one of the most challenging topics in tinnitus clinical studies is the measuring method used. Visual Analogue Scales (VAS) and Tinnitus Handicap Inventory (THI) are frequently used in tinnitus.

Attending to the high prevalence of tinnitus (about 80%) in sudden hearing loss cases, and the controversy about the most effective therapeutic options in reduction and/or remission of symptoms of hearing loss and tinnitus, this research aimed to characterize the tinnitus and its evolution in 11 patients treated by oral corticosteroid and/or intratympanic corticosteroid, as salvage treatment after failure in oral treatment.

Materials and Methods

This is an analytical and retrospective study and was approved by the institutional review board of the Medical School and the University Hospital in which it was carried out.

All patients received information about the risks and expectations of therapy and signed a free informed consent form. A detailed clinical history was taken, followed by an otoneurological examination and an initial audiological assessment by pure-tone audiometry, speech audiometry and an image exam (magnetic resonance imaging with contrast of the inner auditory canal).

All patients were treated with systemic therapy according to the local protocol (1mg/kg/day prednisolone for 10 days, followed by decreasing doses thereafter). (Oral steroids/ OS)

Next, salvage therapy with intratympanic methylprednisolone

(oral steroids more intratympanic methylprednisolone/OS+IT) was offered to six patients with a diagnosis of SHL, after systemic therapy failed and no improvements were demonstrated audiometrically. The patients signed the free informed consent form to be included in this study. Below are the details of inclusion criteria, the audiometric assessment, application technique, analysis of the Tinnitus Handicap Inventory (THI) and Visual Analogue Scale (VAS) for tinnitus and outcome of recovery of hearing loss and tinnitus.

Audiometric Analysis

All patients underwent pure-tone audiometry and speech audiometry recognition rate analysis done by audiologists before and after treatment. The tritonal mean was calculated based on pure-tone average at 0.5, 1.0 and 2.0 KHz. The speech recognition score (SRS) was based on the percentage of correct answers for monosyllables.

Technique

Prior to any procedure, patients were oriented as to the risks and expectations about the procedure and signed a free informed consent form. EMLA cream (Astra Zeneca, Wilmington DE) was applied for topical anesthesia. EMLA cream was placed in the outer ear canal and the tympanic membrane and left for 30 to 45 minutes, after which it was removed. Next, the patient's head was placed at 45° towards the unaffected ear. A 40 mg/mL methylprednisolone solution was warmed to body temperature in a water bath. About 0.3 to 0.5 mL of the solution was injected into the middle ear; two orifices were made with the drug application needle (Gelco N.22), one immediately below the umbus (where the drug will be administered) and another on the postero-superior region (vent hole). No ventilation tubes were needed.

After intratympanic application of the steroid, the patient remained in the supine position and cervical rotation at 45° for 30 minutes to maximize exposure of the round window membrane to the solution. A second injection was done if there was any possibility that the first injection was not adequate. Patients were asked to avoid water in the treated ear for at least two weeks.

Definition of Improvement (analysis of recovery)

The criteria for defining successful recovery after therapy vary in the literature on corticotherapy. A 20 dB improvement at 0.5, 1.0 and 2.0 KHz, or a 20% improvement in discrimination was enough to consider the intervention as successful. Failure of oral prednisolone therapy was absence of improvement, as just described, after 14 days of treatment.

All patients underwent a Tinnitus Handicap Inventory Questionnaire (THI) and the Visual Analogue Scale (VAS) to assess quantitatively and qualitatively the therapy [7,8]. In the VAS score ranges from 1 to 10, where 10 represents the highest degree of tinnitus severity. Scores are obtained regarding the intensity and discomfort of tinnitus. The reduction of two points was considered improvement [8].

Results

The sample consisted of 11 patients, with five in OS group and 6 in OS + IT. Regarding gender 60% were male and 40% women in OS group. While 50% were male and 50% were female in OS + IT group. The age ranged from 26-66 years with an average of 36.2 years in OS group and from 30 to 54 years with a mean of 43.5 years in OS + IT group. The most affected was the right ear in the OS group (n = 5) (100%) and left in OS + IT group (n = 6) (83.3%).

All patients had tinnitus (100%) associated with sudden hearing loss, and three (27%) showed tinnitus as main complaint. All patients reported that tinnitus was located in the affected ear and had concomitant sudden onset hearing loss. None of the participants received specific treatment for tinnitus. Approximately 73% of respondents could not identify an effective strategy for relief from tinnitus and 27% related masking sounds as effective.

Regarding the THI scores, it ranged from 6 to 98, prior to initiation of therapy, and from 4 to 84 points 90 days after the onset. It was possible an average difference of 13.2 points between pre and post THI and 26.5 points among patients who reported an improvement in tinnitus before and after therapy (Table 1, Figure 1).

In relation to the mean-tone, obtained as a result of the following classifications: mild (18,1%), moderate (27,3%), severe (27,3%) and deep (27,3%) (Figure 3). Nine patients had improvement in the pure tone thresholds, and in six patients improvement of hearing was significant, 3 OS and 3 OS + IT (Figure 2, Figure 3).

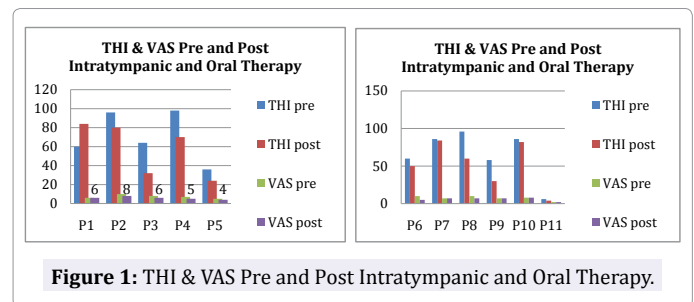


Figure 1: THI & VAS Pre and Post Intratympanic and Oral Therapy.

Patients	Therapy	Age (years)	Gender	Delay onset-therapy	Affected Ear	THI Pre-therapy		THI Post-therapy		VAS		Média tritonal	
						Classification	Grau	Pré	Post	Pre	Post-		
1	VO	26	M	2 days	R	60	(4) Severe	84	(5)Catastr.	6	6	Moderate	Moderate
2	VO	34	M	1 day	R	96	(5) Catastr.	80	(5)Catastr.	10	8	Moderate	Moderate
3	VO	26	F	1 day	R	64	(4) Severe	32	(2) Mild	8	6	Mild	Normal
4	VO	29	M	3 days	R	98	(5) Catastr.	70	(4) Severe	7	5	Profound	Moderate
5	VO	66	F	1 day	R	36	(2) Mild	24	(2) Mild	5	5	Mild	Normal
6	VO + IT	53	F	0 days	L	60	(4) Severe	50	(3)Moderate	10	5	Moderate	Moderate
7	VO + IT	30	F	3 days	L	86	(5) Catastr.	84	(5)Catastr.	7	7	Severe	Severe
8	VO + IT	37	M	0 days	L	96	(5) Catastr.	60	(4) Severe	10	7	Profound	Profound
9	VO + IT	43	M	0 days	L	58	(4) Severe	30	(2) Mild	7	7	Severe	Normal
10	VO + IT	44	F	2 days	L	86	(5) Catastr.	82	(5)Catastr.	8	8	Severe	Severe
11	VO + IT	54	M	1 day	R	06	(1) Light	04	(1) Light	5	5	Profound	Mild

Table 1: Characterization of the Tinnitus (THI & VAS)
Catastr. - Catastrophic

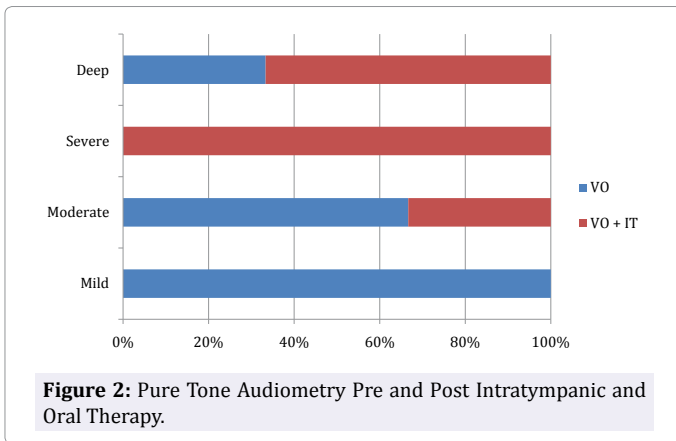


Figure 2: Pure Tone Audiometry Pre and Post Intratympanic and Oral Therapy.

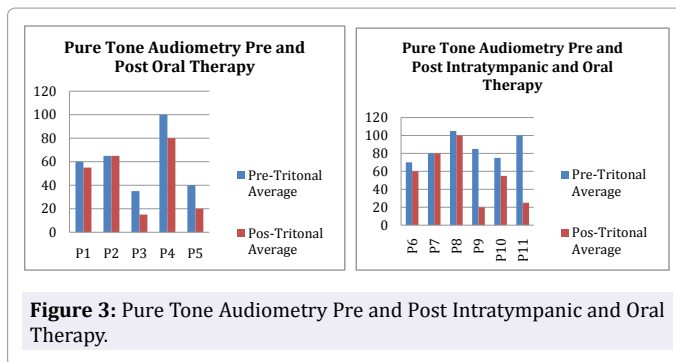


Figure 3: Pure Tone Audiometry Pre and Post Intratympanic and Oral Therapy.

Discussion

Sudden hearing loss mainly occurred in the age group 43-53 years [9], with equal gender distribution, and with no significant difference between male and female subjects in the sample studied. Despite less prevalent, sudden hearing loss is a terrible experience for the patient who perceives it as an abrupt silence, and may be accompanied by tinnitus and/or vertigo, representing not only the loss of inner ear function, but also the impairment of psychological state of the patient [10].

Tinnitus was present in 100% ($n = 11$) of the sample, with scores equal to or above five on the Visual Analogue Scale (VAS) and the sudden hearing loss was accompanied by tinnitus in approximately 80% of cases [3,4].

Currently, in addition to therapeutic approaches such as oral steroids and/or intratympanic methylprednisolone [11] and vasodilators for sudden hearing loss, which are most commonly used options due mainly prescription is easily associated with the low cost; there are still therapeutic approaches such as the use hyperbaric oxygen therapy [3] and cochlear implant [12]. However, corticosteroids seem to have universal acceptance and are the ones with proven effectiveness. Treatments such as diuretics and antiviral drugs may also be included. Such treatments aim to improve the inner ear oxygenation and include vasodilators, plasma expanders, steroids and anticoagulants [13].

In this study, we compared the results between subjects who underwent intratympanic corticosteroid therapy after failure of corticosteroid therapy orally and those who underwent treatment with oral corticosteroids. No significant differences were observed between these two groups. However, an association was observed between the results obtained by the THI and VAS, as can be seen in 5 patients treated with IT + VO and closer correlation in two patients orally, in which there was even hearing improvement (Table 1).

Figureiredo et al. verified the relationship between VAS and THI scores in tinnitus patients in a prospective study in 43 patients classified their tinnitus according to VAS and THI, and both scores were compared through the Spearman's correlation coefficient test. There was a correlation between the VAS and THI scores in patients with sensorineural tinnitus. Several factors may affect the prognosis of the SHL (eg, SHL severity, vertigo, type of audiogram, patient's ages, and symptom's lasting before treatment).

Given the results, we note that in addition to the proposed intervention, especially those cases where there were no improvement or even where there were worsening of symptoms over time, there are other recommended therapies such as cognitive-behavioral and Tinnitus Retraining Therapy. Some therapies for tinnitus tend to focus on the impact of noise on the quality of life and humor, and include antidepressants, anticonvulsants and benzodiazepines, or attempt to mask their own noise with white noise generators. Habituation programs and psychotherapy are almost always recommended [12].

Araújo et al. tested the effectiveness of intratympanic dexamethasone injections as a treatment for severe disabling cochlear tinnitus in thirty-six patients that were randomly assigned to receive intratympanic injections of a dexamethasone solution or isotonic sodium chloride (saline) solution. Improvement of tinnitus was measured with a visual analog scale. The two groups were similar in age, sex, tinnitus laterality, measurement of tinnitus intensity on the visual analog scale, and main otologic diagnosis. Twenty-nine percent of the ears in the saline group and 33% of the ears in the dexamethasone group showed significant improvement immediately after completion of treatment. These measurements were not significantly different from each other. There was no advantage in intratympanic injections of dexamethasone over saline solution in the treatment of severe, disabling tinnitus. Both solutions produced a placebo like improvement [8].

Hikita et al. in 2010, reported that in the group "buzzing rare" there was a worst prognosis to hear than in the group "buzzing often". All subjects had SHL, although the group "short" had a better prognosis than the group "longer duration" when restricted to SHL accompanied by tinnitus. This indicates that the tinnitus, by itself, cannot be a problem in the prognosis of hearing, but may be an essential sound for the early recovery of the damaged auditory system. The 50 patients were treated with systemic administration of steroids [14].

Michiba et al. in 2013, highlighted the fact that many patients are frustrated with the SHL residual buzz, even after complete SHL treatment. It was conducted a prospective study that analyzed gender, laterality and age of patients, along with changes in the level of hearing and tinnitus, after scoring early SHL to determine the prognostic factors of residual tinnitus after the last day of treatment for SHL in 44 patients with SHL were followed, all treated with systemic steroids administration for two weeks and oral ingestion of vasoactive drugs and B12 vitamin for 6 months. The hearing improvement rate was determined by comparing the thresholds before and six months after initiation of treatment. The tinnitus was assessed subjectively by a questionnaire before, six and 24 months after initiation of treatment. The improvement of hearing thresholds were significantly correlated with improvement in the score of tinnitus six months after initiation of treatment compared with before treatment. Among the comparison between six and 24 months after initiation of treatment, there was no significant change. It was concluded that, according to the survey of tinnitus, the time factor is the most reliable item for subjective tinnitus [15].

Rah et al. (2014) investigated the long-term results of tinnitus

in 50 patients with sudden hearing loss (SHL) after treatment with corticosteroids. Patients were divided into two groups satisfied and unsatisfied, according to the degree of improvement of tinnitus after the treatment. Subjective improvement of tinnitus and hearing were investigated before and six months after treatment. The change of tinnitus was assessed using a visual analog scale of intensity and frequency of tinnitus. Patients with more severe hearing loss had lower initial recovery of hearing. The ideal and successful treatment of SHL can be an important factor in obtaining the favorable long-term control of tinnitus accompanied by SHL (16).

Generally, subjective feelings for the ringing residual six months after initiation of SHL treatment are almost the same as 24 months after treatment. Especially younger patients with hearing improvement achieve an improvement of tinnitus in the period between 6 and 24 months after initiation of treatment.

Considering that the research was conducted with a small group of subjects with sudden hearing loss and tinnitus, it is noted that further studies with larger samples and control group are needed to investigate the efficacy of oral and intratympanic steroids in reducing and/or remission of tinnitus in sudden hearing loss.

Conclusion

Patients that carry sudden hearing loss and tinnitus, and underwent intratympanic and oral corticosteroids showed significant reduction of tinnitus in this study.

References

1. Eggermont JJ. Pathophysiology of tinnitus. *Prog Brain Res*. 2007;166:19-35.
2. Schreiber BE, Agrup C, Haskard DO, Luxon LM. Sudden sensorineural hearing loss. *Lancet*. 2010;375(9721):1203-11. doi: 10.1016/S0140-6736(09)62071-7.
3. Maia RA, Cahali S. Surdez súbita. *Braz J Otorhinolaryngol*. 2004; 70:238-48.
4. Penido Nde O, Ramos HV, Barros FA, Cruz OL, Toledo RN. Clinical and etiological factors and evolution of hearing in sudden deafness. *Braz J Otorhinolaryngol*. 2005;71(5):633-8.
5. Rauch SD, Halpin CF, Antonielle PJ, Babu S, Carey JP, Gant BJ, et al. Oral vs intratympanic corticosteroid therapy for idiopathic sudden sensorineural hearing loss: a randomized trial. *JAMA*. 2011;305(20):2071-9. doi: 10.1001/jama.2011.679.
6. Figueiredo RR, Azevedo AA, Oliveira Pde M. Correlation analysis of the visual-analogue scale and the Tinnitus Handicap Inventory in tinnitus patients. *Braz J Otorhinolaryngol*. 2009;75(1):76-9.
7. Paula Erika Alves F, Cunha F, Onishi ET, Branco-Barreiro FC, Ganança FF. [Tinnitus Handicap Inventory: cross-cultural adaptation to Brazilian]. *Pro Fono*. 2005;17(3):303-10. Portuguese.
8. Araújo MF, Oliveira CA, Bahmad FM Jr. Intratympanic dexamethasone injections as a treatment for severe, disabling tinnitus. Does it work? *Arch Otolaryngol Head Neck Surg*. 2005;131(2):113-7.
9. Rauch SD. Clinical practice. Idiopathic sudden sensorineural hearing loss. *N Engl J Med*. 2008; 359:833-40. doi: 10.1056/NEJMcp0802129.
10. Lazarini PR, Camargo AC. Idiopathic sudden sensorineural hearing loss: etiopathogenic aspects. *Braz J Otorhinolaryngol*. 2006;72(4):554-61.
11. Raymundo IT, Bahmad F Jr, Barros Filho J, Pinheiro TG, Maia NA, Oliveira CA. Intratympanic methylprednisolone as rescue therapy in sudden sensorineural hearing loss. *Braz J Otorhinolaryngol*. 2010;76(4):499-509.
12. Ramos A, Polo R, Masgoret E, Artiles O, Lisner I, Zaballos ML, et al. Cochlear implant in patients with sudden unilateral sensorineural hearing loss and associated tinnitus. *Acta Otorrinolaringol Esp*. 2012;63(1):15-20. doi: 10.1016/j.otorri.2011.07.004.
13. Liang CY, Gong Y, Li J, Tian AM. Vasodilator agents for sudden sensorineural hearing loss. *Cochrane Database Syst Rev*. 2002.
14. Hikita-Watanabe N1, Kitahara T, Horii A, Kawashima T, Doi K, Okumura S. Tinnitus as a prognostic factor of sudden deafness. *Acta Otolaryngol*. 2010;130(1):79-83. doi: 10.3109/00016480902897715.
15. Michiba T, Kitahara T, Hikita-Watanabe N, Fukushima M, Ozono Y, Imai R, et al. Residual tinnitus after the medical treatment of sudden deafness. *Auris Nasus Larynx*. 2013;40(2):162-6. doi: 10.1016/j.anl.2012.06.007.
16. Rah YC, Park KT, Yi YJ, Seok J, Kang SI, Kim YH. Successful treatment of sudden sensorineural hearing loss assures improvement of accompanying tinnitus. *Laryngoscope*. 2015;125(6):1433-7. doi: 10.1002/lary.25074.

*Corresponding author: Barreto MA, SMHN QD 02 BLOCO C Ed. Dr. Crispim, Sala 515, Asa Norte, Brasília-DF, CEP 70710-149, Brazil, Tel: 613-328-6009, E-mail: nikebarr@hotmail.com

Received Date: July 01, 2015, Accepted Date: October 21, 2015, Published Date: October 30, 2015.

Copyright: © 2015 Barreto MA, et al. This is an open access article distributed under the Creative Commons Attribution License, which permits unrestricted use, distribution, and reproduction in any medium, provided the original work is properly cited.

Citation: Barreto MA, Ledesma AL, de Oliveira CA, Bahmad Jr F (2015) Corticosteroids Therapy for the Tinnitus Associated with Sudden Hearing Loss. *J Oto Rec Surg* 1(1): 105. <http://dx.doi.org/10.19104/jors.2015.105>.