

Greater Superficial Petrosal Nerve Schwannoma: Case Report and Literature Review

Matheus de Souza Campos¹,
Carlos Augusto Oliveira²,
Luis Augusto Miranda Dias³,
Bernardo Alves Barbosa³ and
Fayez Bahmad Jr⁴

Abstract

Objective: The aim of this study is to present a case of GSPNS, its clinical features, radiological aspects and surgical treatment as well histopathological and immunochemistry findings. Furthermore we present a literature review about this particular type of Schwannomas.

Background: Greater superficial petrosal nerve schwannoma (GSPNS) is a very rare type of facial nerve schwannoma. Only 0.8% of petrous mass lesions are GSPNS. There are only 26 cases reported in literature. These tumors can involve any segment of the nerve. Patients may complain of hearing loss, tinnitus, facial palsy, and headaches, red and dry eyes. The aim of this study is to present a GSPNS case and a pertinent literature review.

Methods and Findings: A 35 years old man complained of tinnitus and hearing loss in the left ear. Examination revealed normal otoscopy and facial mimics. The patient had no dry eyes. MRI showed a solid mass with 2.1 × 1.8 cm in the left middle cranial fossa, which was completely removed. Histology and immunohistochemistry were compatible with Schwannoma. The postoperative course was without complications, no facial palsy, hearing thresholds were slightly worse in left ear and there was reduction of tear secretion.

Conclusion: GSPNS are very rare and demands a high suspicion level of physicians when dealing with patients who have middle cranial fossa tumors. It is imperative to make an appropriate and precise diagnosis, based on clinic and image examination to make a safe decision about surgical management of the lesion.

Keywords: Schwannoma; Middle cranial fossa tumors; Lesions; Otoscopy; Facial nerve; Hearing loss

Abbreviations: GSPNS: Greater Superficial Petrosal Nerve Schwannomas

- 1 Brasiliense Institute of Otorhinolaryngology, Brasilia, Brazil
- 2 University of Brasilia, Brazil
- 3 Brasilia Hospital, Brasilia, DF, Brazil
- 4 Health Science School, University of Brasilia, Brazil

Corresponding author: Bahmad FJ

✉ fayezbjr@gmail.com

Professor, Health Science School, University of Brasilia, Brazil.

Tel: +5561981810700

Citation: Campos MS, Oliveira CA, Dias LAMD, et al. Greater Superficial Petrosal Nerve Schwannoma: Case Report and Literature Review. Neurooncol Open Access. 2016, 2:2.

Received: May 31, 2016; **Accepted:** June 21, 2016; **Published:** June 24, 2016

Introduction

Facial nerve schwannomas are rare and include only 0.8% of all intrapetrous mass lesions [1]. These tumors can arise from any portion of the nerve, from the internal auditory meatus to the parotid gland - the labyrinthine, tympanic, and vertical segments of the facial nerve are the most common affected regions [2]. Lesions originating from the greater superficial petrosal nerve (GSPN) are infrequently described. Patients affected could have several symptoms, among which are hearing loss, tinnitus, facial palsy, headaches, red and dry eyes.

Case Report (Methods and Results)

A 35 year old man was seen in our clinic complaining of left ear hearing loss and tinnitus for the last 10 years. Examination showed normal otoscopy and absence of neurological deficits.

There was neither dry eye nor facial paralysis. Audiometry showed mild sensori-neural hearing loss in the left ear (**Figure 1A and 1B**) tympanometry showed curves type "A" and absence of acoustic reflexes. Brainstem Evoked Response Audiometry (BERA) revealed normal response in the right and prolonged latency of wave 5 in the left side. Vectoelectronistagmography

(VNG) showed normal ocular motility but a left diminished vestibular function.

MRI demonstrated an enhancing solid mass measuring 2.1 × 1.8 cm in the left middle cranial fossa, over the superior edge of the petrous bone with extension to the Internal Auditory Canal. The mass was hypo to isointense in T1 weighted sequency and iso to hyperintense in T2 weighted images (Figure 2). Computed Tomography showed an erosion of the tegmen tympani with invasion of the tympanic cavity next to the ossicular chain.

The patient underwent surgical treatment. The surgery was performed via middle cranial fossa, (intra and extra) dural approach. The lesion was yellowish and solid, with a well defined cleavage plane with the facial nerve.

It seemed to originate in the Glasscock triangle, from greater superficial petrosal nerve, (GSPN) a branch of the facial nerve and it was necessary to perform a trasmastoid approach to remove the intratympanic portion of the tumor.

Histological evaluation revealed proliferation of elongated cells, isolated cells with degenerative atypia and Verocay bodies. Immunohistochemistry was compatible with Schwannoma (Figure 3). The post-operative course had no complications. After surgery the patient had no facial palsy but a slightly worsening in hearing thresholds in the left ear (Figure 1C and 1D) and he started to complain of mild dry eye in the left. Post-operative MRI showed complete removal of the lesion (Figure 4).

Discussion

For literature review we have searched the medline database using the words "Greater Petrosal Nerve Schwannoma". 17 articles have been found, including a Radiology Quiz Case [3], and

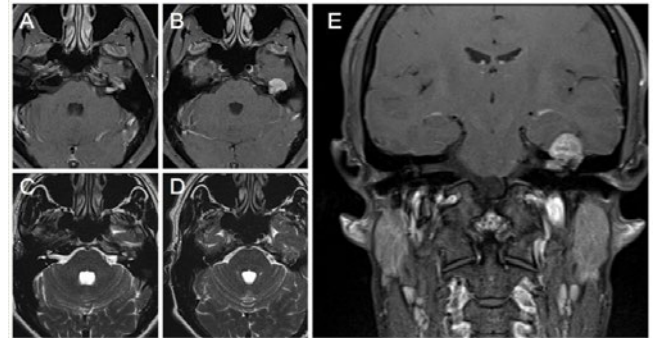


Figure 2 Pre-operative MRI shows a mass hypo to iso-intense on T1-weighted and iso to hyper-intense on T2-weighted images with enhancement after administration of paramagnetic contrast.

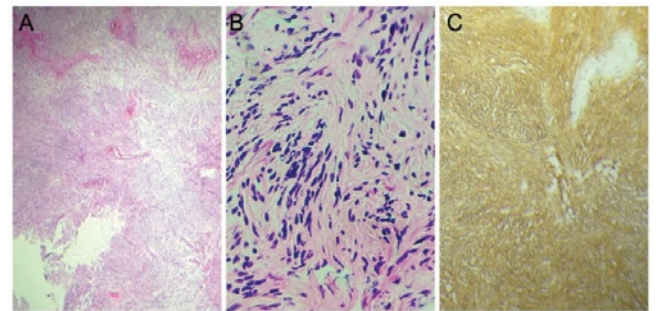


Figure 3 Immunohistochemistry and Microscopy. A: Hematoxylin and Eosin (X40); B: Hematoxylin and Eosin (X400); C: Immunohistochemistry. It is possible to see delineation of Verocay bodies and the cellularity strongly positive for S100.

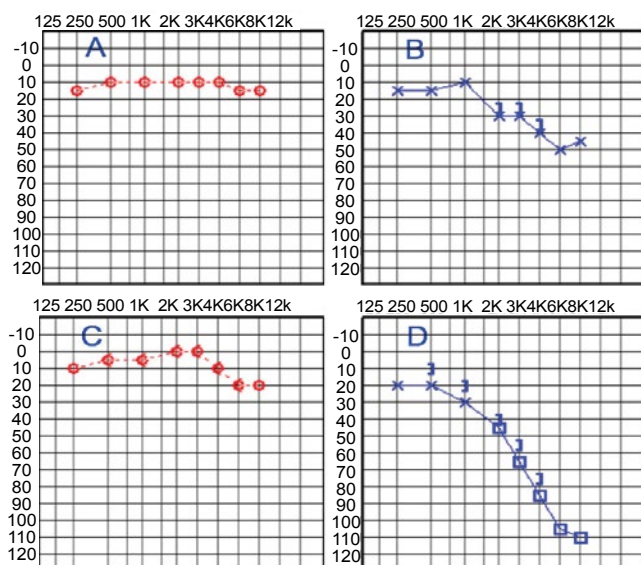


Figure 1 A and B) Pre-operative audiometry showing a mild sensori-neural hearing loss in the left ear (B) and normal threshold in the right ear (A). C and D) Post-operative audiometry shows worsening in hearing (D) thresholds in the left ear and maintenance of levels in the right ear (C).

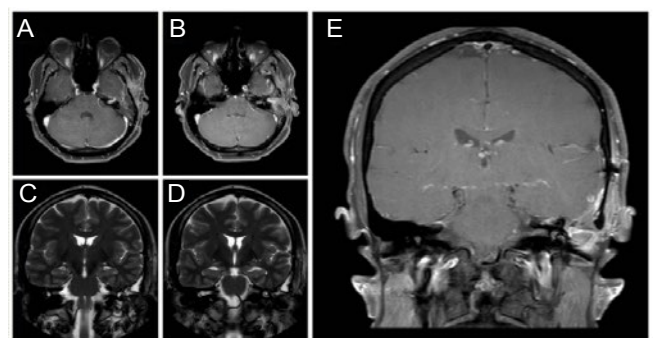


Figure 4 Post-operative MRI shows complete removal of the lesion.

01 case report of a GSPN schwannoma diagnosed with MRI and transtympanic biopsy and treated with stereotactic radiotherapy [4]. Only 26 cases were described in literature (Table 1).

GSPN is the first branch of facial nerve. It arises from the geniculate ganglion carrying both parasympathetic and sensitive fibers, it emerges in the middle cranial fossa occupying the facial hiatus. Then it runs towards foramen lacerum and unites with deep petrosal nerve to form the vidian nerve, which passes through vidian canal to reach the pterygopalatine ganglion and

Table 1 Number of cases of GSPNS in literature.

Cases of GSPNS in literature	No of cases of GSPNS
Tremble and Penfield	01
Kleinasser and Friedman	01
Furlow	02
Kumon et al.	01
Michel et al.	01
Kinouchi	02
Ahahara et al.	01
Schmidinger et al.	01
Mori et al.	01
Sade and Lee	01
Ayberk et al.	01
Amirjamshidi et al.	05
Ichimura et al.	04
De Paulis et al.	01
Umrekdar et al.	02
Kusumi et al.	01
Present case	01

then innervate lacrimal glands and mucosal glands of the nose and palate [5]. In this particular type of Schwannomas, the most common symptoms are facial palsy, hearing disturbances, headaches, dry eyes and possibly diplopia [5]. If the tumor

compresses the abducens nerve. Although xerophthalmia is considered pathognomonic for GSPNS [6,7]. The absence of lacrimation disturbance cannot exclude the possibility of this kind of tumor [8].

Differential diagnosis has to include meningioma of the middle cranial fossa, trigeminal nerve schwannoma, facial nerve schwannoma, primary cholesteatoma and bony tumor of petrous bone [9,10]. These lesions can be differentiated by their MRI and computed tomography characteristics.

According to Ayberk et al. [7], Schwannomas are generally hypo or isointense on T1-weighted and heterogeneously hyperintense on T2-weighted images, and enhanced after administration of gadolinium. Cysts may occur in some parts of the tumor. Generally, the petrous apex is eroded specially by trigeminal nerve schwannomas, while GSPNS affects midportion of the petrous bone [10].

Conclusion

GSPNS are very rare and demands a high suspicion level of physicians when dealing with patients who have middle cranial fossa tumors. It is imperative to make an appropriate and precise diagnosis, based on clinic and image examination to make a safe decision about surgical management of the lesion.

References

- 1 Wiggins RH, Harnsberger HR, Salzman KL, Shelton C, Kertesz TR, et al. (2006) The many faces of facial nerve schwannoma. *AJNR Am J Neuroradiol* 27: 694-699.
- 2 Michel O, Wagner M, Guntinas-Lichius O (2000) Schwannoma of the greater superficial petrosal nerve. *Otolaryngol Head Neck Surg* 122: 302-303.
- 3 Wittekindt C, Liu WC, Hampl JA, Guntinas-Lichius O (2006) Radiology quiz case 1: Intracranial schwannoma originating from the greater petrosal nerve. *Arch Otolaryngol Head Neck Surg*. 132: 102-104.
- 4 Parikh PP, Amber KT, Angeli SI (2013) A schwannoma of the greater petrosal nerve located within the petrous apex and treated with stereotactic radiotherapy. *Am J Otolaryngol*. 34: 596-599.
- 5 Aihara N, Yamada K, Matsuda F, Murakami S (2001) Neurinoma of the greater superficial petrosal nerve developed acute facial palsy: Case report and review of the literature. *Skull Base* 11: 77-80.
- 6 De Paulis D, Di Cola F, Marzi S, Ricci A, Coletti G, et al. (2011) A rare case of greater petrosal nerve schwannoma. *Surg Neurol Int* 2: 60.
- 7 Ayberk G, Ozveren MF, Uzum N, Tosun O, Akcay EK (2008) Cellular schwannoma of the greater petrosal nerve presenting with abducens nerve palsy and xerophthalmia: case report. *Neurosurgery*, p: 63.
- 8 Ichimura S, Yoshida K, Sutiono AB, Horiguchi T, Sasaki H, et al. (2010) Greater petrosal nerve schwannomas-analysis of four cases and review of the literature. *Neurosurg Rev* 33: 477-482.
- 9 Umredkar A, Singla N, Gupta SK, Radotra B (2011) Greater superficial petrosal nerve schwannoma: report of two cases and literature review. *Neurol India* 59: 786-788.
- 10 Schmidinger A, Deinsberger W (2005) Greater superficial petrosal nerve schwannoma. *Acta Neurochir (Wien)* 147: 659-663.